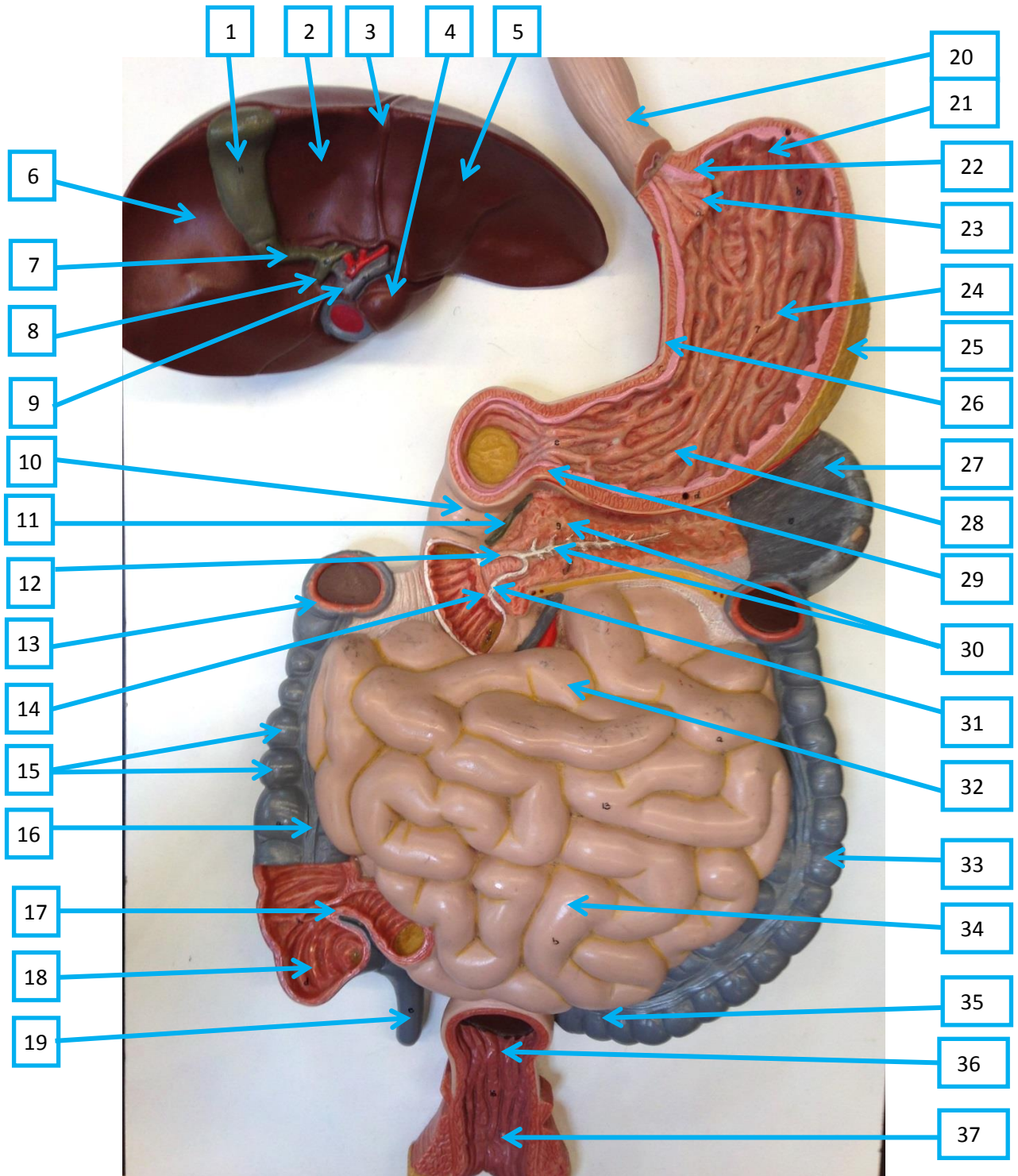


# Digestive System Model (lower 1/2)



## Key

- |                                    |                                      |  |
|------------------------------------|--------------------------------------|--|
| 1. Gallbladder                     | 13. Transverse colon (cut)           | 25. Greater omentum attached to greater curvature of the stomach |
| 2. Quadrate lobe of liver          | 14. Major duodenal papilla           | 26. Lesser curvature of the stomach                              |
| 3. Falciform ligament              | 15. Ascending colon (with haustra)   | 27. Spleen   |
| 4. Caudate lobe of liver           | 16. Teniae coli of ascending colon   | 28. Pyloric antrum   |
| 5. Left lobe of liver              | 17. Ileocecal sphincter (valve)      | 29. Pyloric sphincter  |
| 6. Right lobe of liver             | 18. Cecum                            | 30. Pancreas and pancreatic duct                                 |
| 7. Cystic duct                     | 19. Appendix                         | 31. Hepatopancreatic ampulla                                     |
| 8. Common bile duct                | 20. Esophagus                        | 32. Jejunum  |
| 9. Hepatic portal vein             | 21. Fundus of the stomach            | 33. Descending colon   |
| 10. Duodenum                       | 22. Lower esophageal sphincter       | 34. Ileum  |
| 11. Common bile duct               | 23. Cardia of the stomach            | 35. Sigmoid colon  |
| 12. Accessory duct of the pancreas | 24. Body of the stomach (with rugae) | 36. Rectum   |
|                                    |                                      | 37. Anal canal   |